

Comparison of Operative versus Non-Operative Treatment for Lumbar Canal Stenosis

- DR NEERAJ RAM BIJLANI

Dissertation Submitted for MCH-ORTH (USAIM)

INTRODUCTION

Backache has been the scourge of mankind ever since he assumed the erect posture. The pain has troubled patients and treating doctors alike. Pinpointing the cause of backache and treating it successfully has been their constant endeavor.

Degenerative disease of the spine is one of the common and more frequently encountered causes of low back pain in elderly. With the median age of population rising and more elderly people maintaining an active life style functional limitation due to symptomatic degenerative disease of spine is becoming more common. Lumbar canal stenosis remains one of the most frequently encountered clinically important degenerative spinal disorders in the aging population.

Lumbar canal stenosis is the terminology used to describe developmental or congenital narrowing of the spinal canal that produces compression of the neural elements before their exit from the neural foramen. The narrowing may be limited to a single motion segment or it may be more diffuse spanning two motion segments or more.

Treatment is aimed at not only obtaining immediate pain relief but also to prevent long term disabling sequelae such as chronic backache and spinal instability. With advances in our understanding of pathoanatomy and the clinicopathological correlation, the treatment has changed from various non-operative modalities to decompression and subsequently to decompression and fusion with or without instrumentation.

The present dissertation is a study of 40 cases of lumbar canal stenosis treated over a period of two and half years either by nonoperative modality or by operative modality such as decompression and fusion with or without instrumentation if required.

CLASSIFICATION

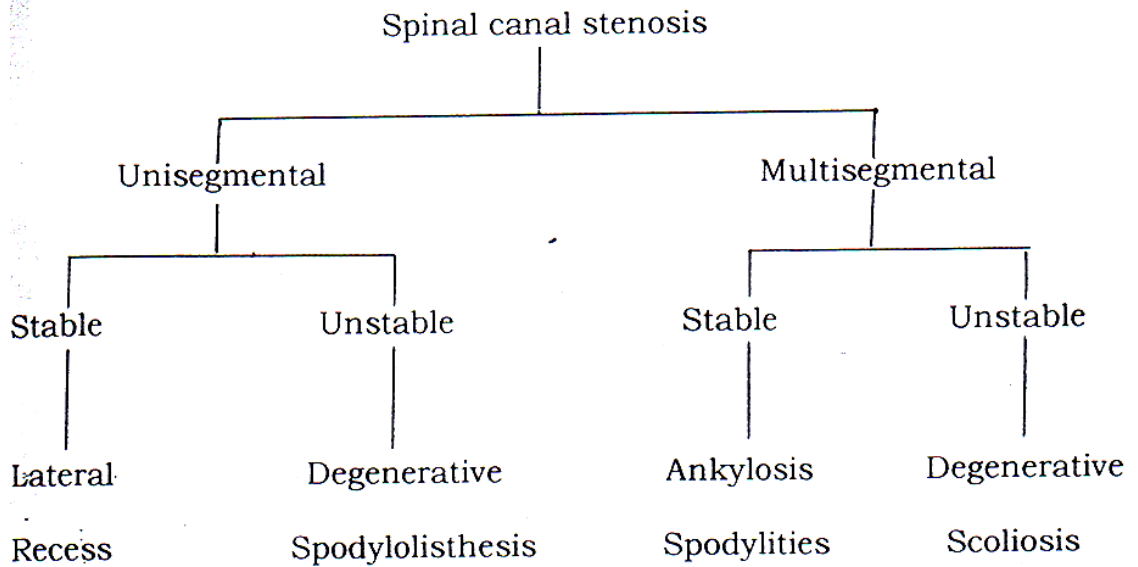
Spinal stenosis is classified according to

1. Etiology
2. According to stability.
3. Site of stenosis
4. Anatomical classification.
5. Anatomical classification.

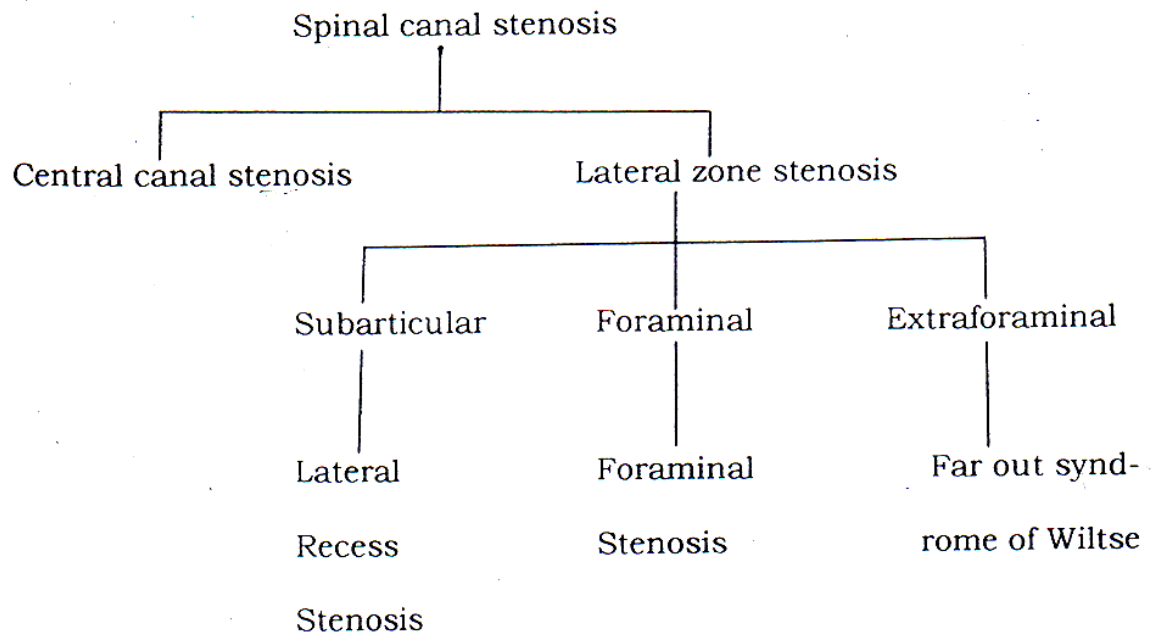
Etiological classification

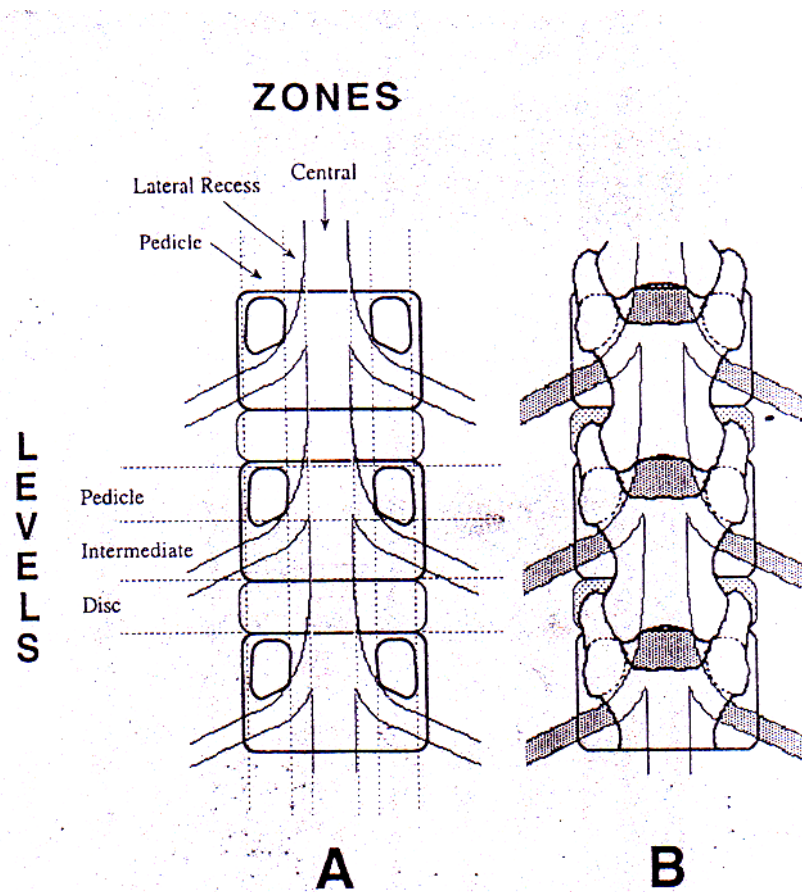
1. Congenital / Developmental stenosis
 - A. Idiopathic
 - B. Achondroplastic
2. Acquired stenosis
 - A. Degenerative
 - B. Spondylolisthetic / Spondylolytic
 - C. Combined
 - D. Iatrogenic
 1. Post – laminectomy
 2. Post-fusion
 - E. Post traumatic
 - F. Miscellaneous
 1. Pagets disease
 2. Flourosis
 3. Foresters disease
 4. Diffuse Idiopathic Skeletal Hyperostosis.

Stability wise classification



Classification according to site:





**LINE DIAGRAM DEMONSTRATING GRID LIKE
SUBDIVISION OF LUMBAR CANAL INTO
THREE ZONES AND THREE LEVELS.**

**THREE ZONES LATERAL SPINAL CANAL
UPPER CIRCLE – ENTRANCE ZONE
MIDDLE CIRCLE – MIDDLE ZONE
LOWER CIRCLE – EXIT ZONE**

Anatomical classification

Anatomical classification of lumbar canal stenosis is used to identify specific areas of narrowing of spinal canal and is particularly useful as guides for operative decompression. Spinal canal is divided in grid like manner into series of transverse (three levels from cephalad to caudad and sagittal region (three zone from midline laterally)).

The three transverse levels from cephalad to caudad are the pedicle level, the intermediate level (body) and the disc level. The pedicle level extends from the superior to the inferior border of the pedicle. The intermediate level extends from inferior border of the pedicle to inferior end plate of the vertebra caudally. The disc level begins at the inferior end plate and extends caudally to the superior border of the next pedicle.

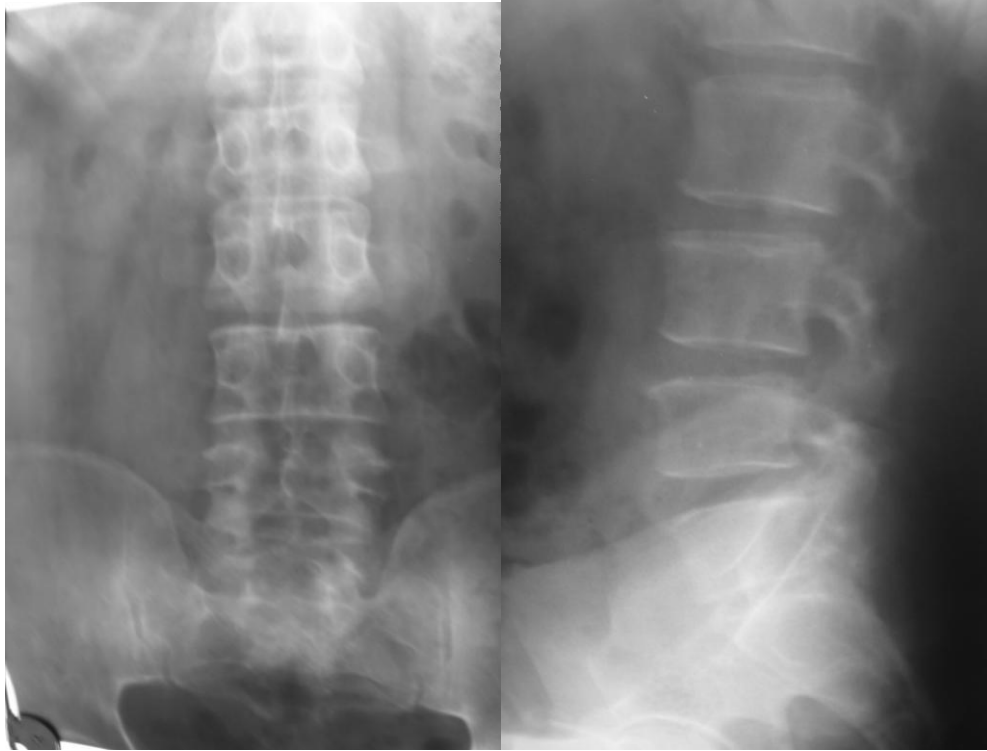
From midline laterally the three sagittal zones are central zone, lateral recess zone, and the pedicle zone. The central zone is the area between normal lateral borders of non-compressed dural sac. The lateral recess zone is the area between the lateral border of the dural sac medially and longitudinal line connecting the medial edges of the pedicle laterally. The pedicle zone is the area between medial and lateral borders of the pedicle. This grid like subdivision of spinal canal helps in anatomical localization of stenotic element and consequent effective decompression.

MATERIALS AND METHODS

This is a study of 40 cases of lumbar canal stenosis, which was carried out in the Department of Orthopaedics at Sion Hospital.

Case selection: Case selection was done on the bases of examination and findings.

Clinically the patients had neurogenic claudication, back pain, and/or sciatica as the main complaints. Neurogenic claudication is characterized by pain, weakness and numbness in the legs which comes on with walking and is relieved on sitting down or by flexing forwards. Sensory symptoms precede the motor manifestations in majority of patients. However if the patients continue his activity beyond the appearance of discomfort or parasthesia, the legs may become weak. The examination at this time may disclose sensory deficit and/or loss of reflexes. As the disease progresses some pain may be experienced at rest and weakness on effort become a prominent symptom. Straining rarely aggravates the pain. These patients have bilaterally symmetrical symptoms; however there is paucity of signs. If signs are present then they consist of varying degree of paravertebral muscle spasm with limitation of spine movements and occasionally restriction of straight leg raising test. Motor weakness is not evident peripherally. Impairment of deep tendon reflexes occurs in most patients' ankle reflex being more severely affected. Sensory changes if present are predominant in fifth



**X-RAY FINDINGS SUGGESTIVE OF LUMBAR CANAL
STENOSIS**

AP VIEW

LATERAL VIEW

lumbar and first sacral dermatomes. If there is an associated disc prolapse, the pain is aggravated by coughing, sneezing, straining at stools, lifting heavy weight etc. They have a restricted SLR and have sensory and motor deficits pertaining to the involved roots.

All patients clinically suspected to be suffering from lumbar canal stenosis were subjected to following radiological investigations: **Plain X-rays lumbosacral spine:** following views were taken,

- (1) Anteroposterior view
- (2) Lateral view
- (3) Right oblique view
- (4) Left oblique view
- (5) Flexion view
- (6) Extension view

The following finding on plain x-rays were suggestive of lumbar canal stenosis:

- (1) Presence of hypertrophy of facet joint
- (2) Reduced distance between the pedicle and the facet joint
- (3) Laterally aligned and irregular facet joint
- (4) Reduced distance between the posterior border of vertebral body and anterior border of the superior facet.
- (5) Short stout spinous process and the laminae.
- (6) Reduced distance between the pedicles of adjoining vertebrae.

(7) Associated features of prolapsed disc viz.

Reduced intervertebral disc space

Posterior osteophytes etc.

Once the diagnosis of lumbar canal stenosis was made patient were subjected to conservative line of management which consisted of:

(1) Limitation of activity: It does not mean complete bed rest. It consists of reduced activity in form of

- (a) Avoidance of lifting heavy weights.
- (b) Avoidance of twisting movements.
- (c) Avoidance of repeated forward bending.

(2) Physical therapy: This consisted of

- (a) Hot water fomentation.
- (b) Deep heat (short wave diathermy)
- (c) Massage
- (d) Ultrasonic therapy
- (e) Aerobic exercises which consist of stationary bicycling, brisk walking, swimming, treadmill walking etc. this aerobic exercises release endorphins which relieve pain.
- (f) Williams flexion exercises program
- (g) Posture alteration: Patients are taught to assume a posture of flexion of spine so that a relative increase in spinal canal diameter takes place.

- (3) **Drugs:**
- (a) Anti-inflammatory drugs like Piroxicam, Diclofenac sodium etc.
 - (b) Skeletal muscle relaxants.
- (4) **Lumbosacral Corset:** A lumbosacral frame type belt was given to all patients, which was adjusted in slight flexion. It only serves to remind the patient to restrict lumbar spine movements. The patients were instructed to wear it only when they were -Up and about for a prolonged period and remove it during sleep and regular household activities.
- (5) **Epidural steroids:** This was given to 5 out of 40 patients in the study. The epidural injection is the combination of long acting steroid with an epidural anesthetic agent.

Long acting steroid- Methyl Prednisolone (Depo-medrol)

Anesthetic agent- Lignocaine, Bupivacaine.

The two are mixed together, diluted in 10cc saline and injected into epidural space. Dilution with normal saline helps to increase the volume of injection and break adhesions that interfere with the injection.

The present protocol is to inject three times in the span of 48-72 hours.

Contraindication: Local infections.

Neurologic disease

Bleeding disorder

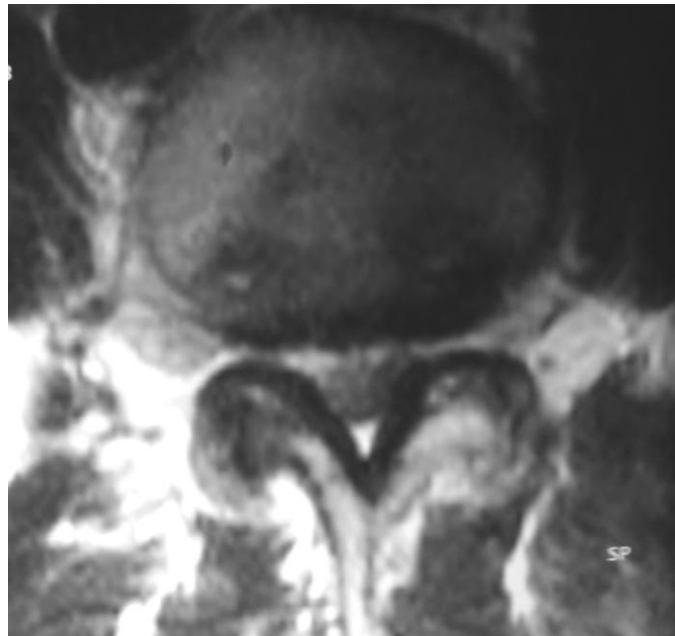
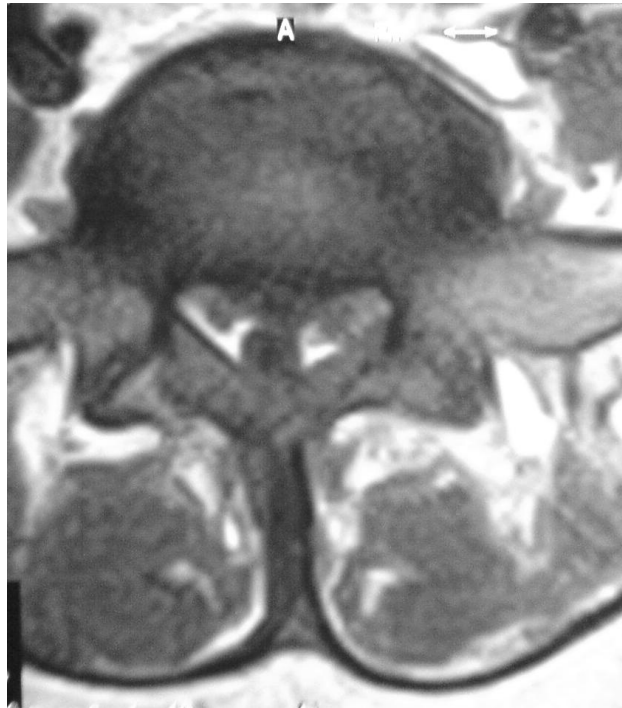Position: Knee -Chest position.

Needle used: 20 or 22 gauge disposable needle.

Technique: With patient in knee-chest position the skin in midline' is anaesthetized. Highest point of the iliac crest is used to locate the interspace between fourth and fifth lumbar vertebrae. The needle is advanced till the resistance of ligamentum flavum is encountered. Then glass syringe is applied to the needle and needle slowly advanced applying light pressure on the syringe. When epidural space is encountered the resistance is suddenly lost and the epidural space will accommodate air. The syringe is detached from the needle to check if CSF comes out. If it doesn't come out, the agent is injected into the epidural space. The needle is withdrawn and tincture benzoin seal is applied.

In our institute epidural steroids injections were given by the anaesthetist. All five patients who were given steroids responded favorably to it.

(6) **Antidepressant drugs:** Low doses of these drugs have beneficial effect on the neurogenic type of pain that is probably related to alteration in membrane characteristics or metabolism. These also have a sedative effect.



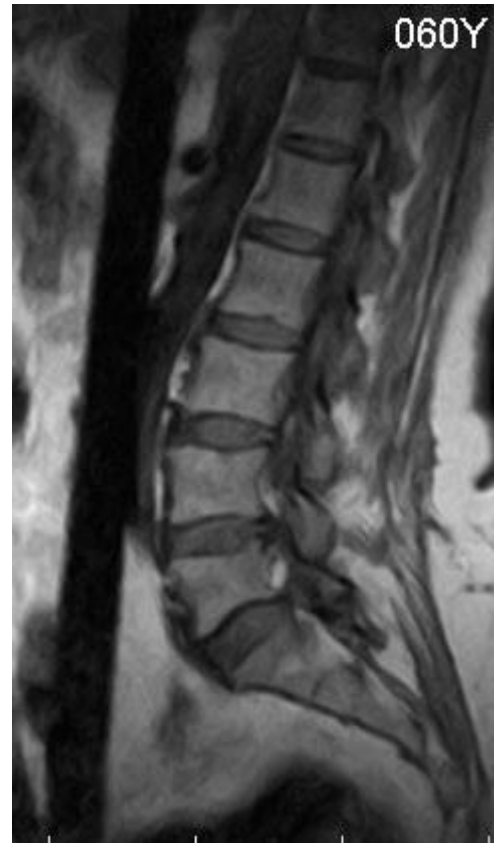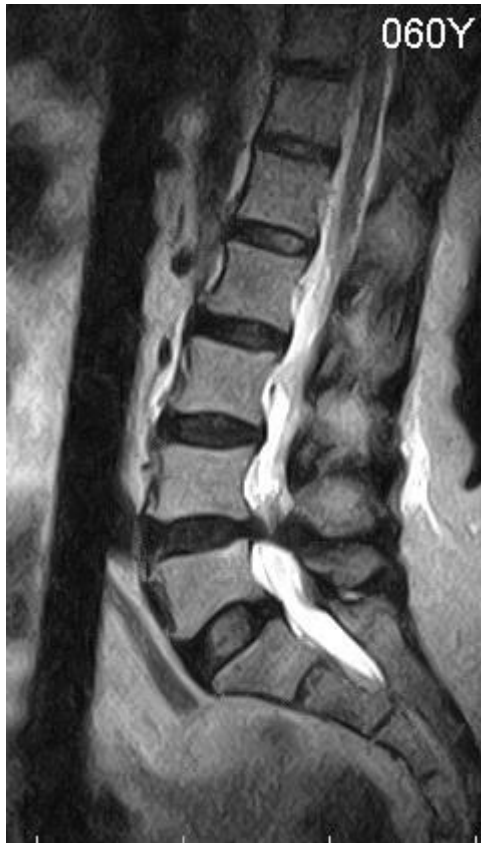MRI FINDINGS SUGGESTIVE OF LUMBAR CANAL STENOSIS CROSS SECTION

7. TENS (Transcutaneous Electric Nerve Stimulation).

All patients were subjected to this conservative line of management and reviewed at the end of 1, 3, 8 & 6 months.

MRI of lumbosacral spine was performed for all 22 patients who were not relieved by conservative management.

The main advantage of MRI over other methods like myelography, myelography with CT scan and Plain CT scan is being its non invasive nature and being radiation free. Also as this investigations were performed only for patients who had not responded to conservative treatment, soft tissue conditions like tumors, infection and pars fracture were ruled out and main disadvantage of MRI, non specificity i.e. high degree of false positive results were negated.



MRI FINDINGS SUGGESTIVE OF LUMBAR CANAL STENOSIS IN SAGGITAL SECTION

OPERATIVE TREATMENT

The surgery was performed only to relieve the patient of his/ her symptoms. Improvement in neurologic status post surgery was an added benefit of surgery.

The surgery consisted of

1. Decompression of the stenosed canal by laminectomy
2. Decompression with fusion.
3. Decompression with fusion with instrumentation.

Surgery for spinal stenosis is one of the more extensive and technically demanding, yet common, procedures performed on the spine. Surgical success hinges on an in-depth understanding of the pathophysiology involved and a thorough knowledge of spinal anatomy. Insight into spinal instability is also required.

An unsuccessful decompressive laminectomy leads to a "failed back" with decreasing rates of good results and increasing disability with each subsequent salvage attempt. This can have particularly disastrous consequences in older patients with their associated complicated medical histories and perhaps already limited function.

OUTCOMES & ANALYSIS

The findings of our study of 40 cases of lumbar canal stenosis were as follows-

Age distribution : The youngest case was 35 years. The oldest being 69 years. The mean age incidence was 45 years.

The distribution in different age groups was,

AGE GROUP	NO. OF PATIENTS
35-40 YEARS	4
40-50 YEARS	21
50-60 YEARS	10
60-70 YEARS	5
TOTAL	40

Sex distribution: there was female preponderance in this study there were 24 females and 16 males in this study.

Duration of pain: Most of the patients had endured the pain for two years. The earliest presentation was at 4 months duration. On an average patient presented after 22 months of pain, the maximum duration being 6 years.

AGE GROUP	NO. OF PATIENTS
0-6 MONTHS	1
6 MONTHS – 1 YEAR	6
1-2 YEARS	21
2-5 YEARS	9
> 5 YEARS	3
TOTAL	40

Type of pain: In the present study 14 patients had only leg pain 18 patients had both leg pain and back pain and 8 patients had only back pain.

TYPE OF PAIN	NO. OF PATIENTS
ONLY LEG PAIN	14
LEG PAIN WITH BACK PAIN	18
ONLY BACK PAIN	8
TOTAL	40

Etiology of lumbar canal stenosis: - Most of the patients in the present study were of degenerative or spondylolytic or combined variety.

ETIOLOGY OF LUMBAR CANAL STENOSIS	NO. OF PATIENTS
CONGENITAL	1
DEGENERATIVE	13
SPONDYLOLYTIC	9
COMBINED	17
IATROGENIC	0
TOTAL	40

Restricted lasegues test: Only 10 patients had restriction of SLR. The rest had unrestricted and free SLR of 90 degrees.

Power and sensations: - 17 patients had slight reduction of power of which 5 had decreased power at rest while 12 had demonstrable weakness of power only after exercise.

23 patients had reduced sensations in either or both the lower limbs.

Deep tendon reflexes were diminished in 36 patients (90%)

Investigations :-

Plain x-rays – all 40 patients.

MRI – In 22 patients who did not respond to conservative treatment and hence were subjected to surgery.

Decompression alone was done in 10 patients.

Decompression with fusion was done in 7 patients.

Decompression with fusion with instrumentation was done in 5 patients.

OPERATIVE TREATMENT	FEMALES	MALES	TOTAL
DECOMPRESSION ALONE	6	4	10
DECOMPRESSION WITH FUSION	4	3	7
FUSION WITH INSTRUMENTATION	3	2	5
TOTAL	13	9	22

Results of treatment:-

	PATIENTS TREATED NON-OPERATIVELY				
	100%	75%	50%	25%	0%
IMPROVEMENT IN					
LEG PAIN	5	4	2	1	2
BACK PAIN	0	1	2	3	6
SENSATIONS	1	2	5	1	0
MOTOR POWER	0	3	1	2	1

	PATIENTS TREATED OPERATIVELY				
IMPROVEMENT IN	100%	75%	50%	25%	0%
LEG PAIN	9	6	2	1	0
BACK PAIN	3	7	2	2	0
SENSATIONS	2	6	4	0	1
MOTOR POWER	1	3	4	0	1

Complications: In our study only one patient had complication. He had superficial wound infection that was successfully treated conservatively with higher antibiotics and daily dressings.

This has been a very recent study and none of the patients had any new neurological deficits at that vertebral level or any other level during a follow up post surgery.

Post-operative X-rays- X-rays of lumbo-sacral region was taken on 2nd postoperative day to evaluate the decompression achieved and to demonstrate the bone graft.

DISCUSSION

A study of 40 cases was made of patients with lumbar canal stenosis. The diagnosis of lumbar canal stenosis was based on clinical findings and supported by radiological investigations.

Comparison of age distribution:

AGE	KATZ ET AL	CAPUTY ET AL	EPSTEIN ET AL	YAMADA ET AL	PRESENT STUDY
MINIMUM	55	43	17	58	35
MAXIMUM	89	84	51	70	69
MEAN	69.3	67	35	62.5	45

Comparison of sex distribution:

We had female preponderance. This was in agreement of the series by Hopp et al but most of the other series also had female preponderance except for Johnson's study, which has male preponderance.^{18, 3, 21, 20}

AGE	JOHNSON AL	HOPP ET AL	CAPUTYET AL	KATZ ET AL	PRESENT STUDY
MALES	24	38	46	26	16
FEMALES	8	62	54	62	24

Most of the patients suffered from chronic pain (lasting more than 4 months).

In our study the average duration was 1 year and 10 months. This is compatible with most of the other studies.^{3, 5, 20, 30}

Comparison of duration of pain prior to operation

DURATION IN MONTHS	CAPUTY ET AL	CIRIC ET AL	JOHNSON ET AL	YAMADA ET AL	PRESENT STUDY
MINIMUM	1	6	4	7	4
MAXIMUM	144	120	96	144	72
MEAN	6	48	22	44	22

Clinically there is a host of symptoms but there is paucity of signs. Neurologically the patient may have some sensory or motor symptoms but are not congruous with the severity of symptoms. This disparity between symptoms and signs is of diagnostic importance. The SLR maneuver is typically normal or nearly so as per Charles Wilson.¹⁹ The SLR may be restricted in case of compression of lateral recess.^{5, 13, 30}

Comparison of SLR restriction

SLR RESTRICTION	CIRIC ET AL	EPSTEIN ET AL	YAMADA ET AL	PRESENT STUDY
TOTAL CASES	16	12	5	40
RESTRICTED SLR	2	8	1	10

Non-operative treatment of lumbar canal stenosis consisted of:-

1. Limitation of activity
2. Physical therapy

- A. Deep heat (SWD).
 - B. Ultrasonic Therapy.
 - C. William's Flexion Exercise Program.
3. NSAIDS.
 4. Lumbosacral corset
 5. Epidural Steroids

The non-operative treatment was given to all 40 patients in this study, only 18 patients responded to it as in this patients the inflammatory, component of soft tissue had caused compromised canal diameter in relatively narrow canal. Non-operative treatment is not useful when irreversible bony and soft tissue changes have already occurred.

Investigations:

Patients who did not respond to conservative treatment were subjected to following investigations,

1. Plain X-ray: The following X-rays of lumbosacral spine were taken. (A) Anteroposterior view
(B) Lateral view in flexion
(C) Lateral view in extension (D) Rt. Oblique view

(E) Lt. Oblique view

The oblique views particularly helped us to visualize the facet joint pathology more clearly under flexion and extension views are useful for picking up latent instability of the lumbar spine.

2. MRI: Only to confirm the extent of lumbar canal stenosis in cases where diagnosis was already made clinically.

After confirming irreversible bony and soft tissue compression of nerve roots patients who did not respond to conservative treatment were subjected to surgery in the form of,

- (a) Decompression
- (b) Decompression with fusion
- (c) Decompression with fusion with instrumentation

The decision regarding fusion of the spine was based on clinical findings and the occupational demands of the patients.

We graded the symptomatic improvement as per relief of pain, return to work, and need to take analgesic drugs. Results were termed as,

- (a) Excellent: If there was occasional pain leading the patient to take analgesics rarely.

- (b) Good: If patient had marked relief of pain but required to take analgesics regularly.
- (c) Fair: If patient had mild relief from pain but was still physically incapacitated and required analgesics regularly.
- (d) Same: If the patient did not improve after surgery.
- (e) Worse: If the patient deteriorated after surgery.

We had 15 excellent results and rest were good results. This compared very well with the study of other authors. (5, 30, 16, 12)

COMPARISON OF IMPROVEMENT OF PAIN

PAIN RELIEF	CIRI C ET AL	YAMADA ET AL	EPSTEIN ET AL	HARRY ET AL	PRESENT STUDY
EXCELLENT	13	5	11	13	15
GOOD	2	0	3	22	7
FAIR	0	0	1	13	0
SAME	0	0	0	0	0
WORSE	1	0	0	2	0
TOTAL	16	5	15	50	22

We had only one case with complication. Patient developed superficial wound infection which was treated conservatively with daily dressing and antibiotics as per sensitivity report. The wound healed uneventfully. Patient had followed up with occasional back pain but was neurologically normal.

CONCLUSION & RECOMMENDATIONS:

Lumbar Canal stenosis is a progressive degenerative disorder of the spine most frequently causing morbidity in middle aged and elderly. The diagnosis is essentially clinical and only supported by radiological investigations.

Non-operative line of treatment is effective for relief of symptoms in most patients in whom inflammatory edema of nerve roots cause compromised canal diameter in a relatively narrow canal. But the pain relief and recovery of sensation and weakness is not as good as in those subjected to surgery especially when radiological evidences of irreversible bony and soft tissue changes are already present.

Surgery for lumbar canal stenosis is performed only when patient has reached the state of disability i.e. patient is unable to carry out his day-to-day activities due to pain. Limited operative decompression with retention of stabilizing elements may decrease short term morbidity but lead to long term failure due to recurrent stenosis or development of stenosis at an adjacent level. Decompression of the stenotic lumbar canal along with fusion is definitely better than decompression alone, specially so in patients having degenerative lumbar spinal stenosis with Spondylolisthesis or Degenerative scoliosis. Pedicle instrumentation after laminectomy provides segmental fixation, improves the rate of fusion and avoids the need to extend fusion to adjacent normal levels.

Surgery is aimed only at providing relief of symptoms and not for achieving improvements in neurological status. If any neurological improvement occurs it is to be regarded as an additional bonus benefit of the surgery.

BIBLIOGRAPHY

1. **Eben Alexander:** Significance of small lumbar canal- cauda equina compression syndrome due to spondylosis part 4:Journal of neurosurgery: Nov 1969: pg. 513-519.
2. **R. Joffe,A.Appleby, and V. Arjona:** Intermittent ischemia of cauda equina due to lumbar canal stenosis: Journal of Neurology, neurosurgery and psychiatry: 1966; 29; pg. 315-318.
3. **Anthony J Caputy, Alfred J Lussenehop;** Long term evaluation of decompressive surgery for degenerative lumbar canal stenosis; Journal of neurosurgery; 1992; pg. 669-676
4. **Kemp Clark;** Significance of the small lumbar canal- cauda equina compression syndrome due to spondylosis. Part 5; Journal of neurosurgery ; Vol 31 ; Nov 1969; pg. 495-498.
5. **Ivan Ciric, M. D., Michel A. Micheal, M.D., Nicolas A Vick ;** The lateral recess syndrome, a variant of lumbar stenosis ; A Journal of neurosurgery ; Oct 1980 ; pg. 433-443.
6. **Ivan Ciric, M. D., Michel A. Micheal, M.D.** The lateral recess syndrome ; Text book of neurosurgery pg.2279-2282.
7. **Rick B Delamarter; John E Sharman ;** Lumbar canal stenosis secondary to calcium pyrophosphate deposition ; CORR ; No. 289 ; pg. 127-130.

8. **Larry D Dodge, Henry H Bohlman** ; Concurrent lumbar canal stenosis and peripheral vascular disease ; CORR ; May 1998; pg. 141-148.
9. **M Judith; Donovan , Donald O Vining** ; A comparison of radiographic method of diagnosing constrictive lesions of spinal canal ; Journal of neurosurgery ; 1978 ; pg. 360-368.
10. **George Ehn; M.D.,** ; Significance of small lumbar canal ; Cauda equina compression syndrome due to spondylolysis Part 1 ; Journal of neurosurgery; Vol. 31; pg. 490-494.
11. **George Ehn; M.D., ; Significance of small lumbar canal;** Cauda equina compression syndrome due to spondylolysis Part II ; Journal of neurosurgery; Vol. 31 ; pg. 507-512.
12. **Joseph A Epstein, Bernard S Epstein, M.D.,** ; Sciatica caused by nerve root entrapment in lateral recess ; Superior facet syndrome; Journal of neurosurgery ; May1972; Pg. 584-589.
13. **Joseph A Epstein, Bernard S Epstein, M.D.,;** Lumbar nerve root compression at the intervertebral foramen caused by arthritis of posterior facet joint ; Journal of neurosurgery ; Sept. 1973 ; 262-368.
14. **Joseph A Epstein, Nancy S Epstein, M.D.;** Lumbar spondylosis and spinal stenosis; Text book of neurosurgery; Pg. 22722278.
15. **Hardy R W, Davis C H** ; Extra articular spinal cord compression from benign lesion of the lumbar area; neurological surgery ; Pg. 2664-2693.

16. **Hary N Hermowitz, Lawrence T Kurz,M.D.;** Degenerative lumbar Spodylolisthesis with spinal stenosis ; JBJS : July 1991 ; Pg. 802-808.
17. **Hing K . Y , W.H Kirkaldy Willis ;** Anatomy pathology and pathogenesis of lateral recess stenosis ; Posterior lumbar interbod_y fusion ; Edited by Paul M Lin ; Pg. 163-177.
18. **Emery Hopp, M.D., Paul M Tsou, ;** Post decompression lumbar instability ; CORR ; Feb 1988 ; Pg. 143-151.
19. **Inderbir Singh ; An introduction to human Embryology ;** 2nd edition.
20. **Johnson Karl Ingmar Rosen ;** The natural course of lumbar canal stenosis ; CORR- 279 ; June 1992 ; Pg. 82-86.
21. **Jeffery N. Katz, Stephen J Lipson ;** Outcome of decompressive laminectomy for degenerative lumbar stenosis ; JBJS-July 1991; Pg, 809-816 .
22. **Lin. P. M ;** Introduction, Biomechanics, Principles And Indications of posterior lumbar interbody fusion ; Pg. 3-57.)
23. **Rothman;** Spinal stenosis surgery ; The spine ; Pg. 819-840.
24. **Joseph T.Schatzker, George F.Pennal;** Spinal stenosis- a cause of cauda equina syndrome; JBJS- Vol 50 B ; Aug 1968; Pg. 606-618.
25. **Phillip T. Schlensinger, Glens Fall ;** Lumbar nerve root compression and adequate operative exposure; JBJS-1957 A ; Pg. 541-553.
26. **Verbiest Hank ; Lumbar canal stenosis ;** Textbook of neurosugery III Edition ; Pg. 2805-2855.

27. **Verbiest Hank** ; Results of surgical treatment of Idiopathic developmental Lumbar canal stenosis ; JBJS - May 1977 ; Pg. 181-188.
28. **Wilson Charles B** ; Significance of small lumbar canal stenosis ; Cauda equina compression svndrome due to spondylolysis Part III ; Journal of neurosurgery; Vol. 31; pg. 699-706.
29. **Hiroshi Yamada** ; Masaki Ohya ; Intermittent cauda equina compression due to narrow spinal canal ; Journal of neurosurgery ; July- 1972 ; Pg. 83-87.
30. **Campbell:** Operative orthopedics 9t' edition ; Pg. 3142-3151.
 31. Jeffrey M Spivak. M.D ; Current concepts Review - Degenerative Spinal Stenosis; JBJS ; Vol 80-A ; July-1998 ; Pg. 1053-1066.
 32. Harry N Herkowitz, Steven R Garfin ; Rothman-Simeone : The Spine 1999 Edition ; Pg 779-806.
33. **Eddward V Benzel** ; Spine Surgery ; Is' Edition ; Pg 306-331

MASTER CHART

S.R. NO.	NAME	SEX/ AGE	ETIOLOGY OF LCS	DURATION OF PAIN	TYPE OF PAIN	RESTRICTED SLR	TREATMENT GIVEN
1)	SAVITRIBAI	F/45	COMBINED	1-2 Years	ONLY LEG PAIN	PRESENT	CONSERVATIVE
2)	PADMAJA	F/42	SPONDYLOLYTIC	6-months-1 year	ONLY BACK PAIN	ABSENT	CONSERVATIVE
3)	REHMAN	M/54	COMBINED	2-5 years	BACK & LEG PAIN	ABSENT	DECOMPRESSI ON ONLY
4)	SUNANDA	F/38	SPONDYLOLYTIC	1-2 Years	ONLY BACK PAIN	ABSENT	CONSERVATIVE
5)	ANAND	M/45	COMBINED	1-2 years	BACK & LEG PAIN	ABSENT	DECOMPRESSI ON, FUSION & INST.
6)	ALTAF	M/35	SPONDYLOLYTIC	6 months-1 year	ONLY BACK PAIN	ABSENT	CONSERVATIVE
7)	JANABAI	F/68	DEGENERATIVE	>5 years	ONLY LEG PAIN	PRESENT	CONSERVATIVE
8)	SHAHIDA	F/40	SPONDYLOLYTIC	1-2 years	ONLY BACK PAIN	ABSENT	DECOMPRESSI ON, FUSION & INST.
9)	RAMAKANT	M/48	COMBINED	1-2 years	BACK & LEG PAIN	ABSENT	DECOMPRESSI ON & FUSION
10)	BHASKAR	M/57	DEGENERATIVE	2-5 years	ONLY LEG PAIN	PRESENT	DECOMPRESSI ON ONLY
11)	TERESA	F/46	COMBINED	1-2 years	BACK & LEG PAIN	ABSENT	CONSERVATIVE
12)	PRIYA	F/36	CONGENITAL	1-2 years	BACK & LEG PAIN	ABSENT	DECOMPRESSI ON ONLY
13)	NARAYAN	M/45	COMBINED	1-2 years	BACK & LEG PAIN	ABSENT	CONSERVATIVE
14)	TARAMATI	F/51	COMBINED	2-5 years	BACK & LEG PAIN	ABSENT	DECOMPRESSI ON ONLY
15)	RAVINDRA	M/60	DEGENERATIVE	>5 years	ONLY LEG PAIN	PRESENT	DECOMPRESSI ON ONLY
16)	DATTARAM	M/41	SPONDYLOLYTIC	6 months-1 year	ONLY BACK PAIN	ABSENT	CONSERVATIVE
17)	VINAYAK	M/47	COMBINED	1-2 years	BACK & LEG PAIN	ABSENT	DECOMPRESSI ON, FUSION & INST.
18)	RASHIDA	F/57	DEGENERATIVE	2-5 years	ONLY LEG PAIN	PRESENT	CONSERVATIVE
19)	RAJANI	F/45	COMBINED	1-2 years	BACK & LEG PAIN	ABSENT	DECOMPRESSI ON ONLY
20)	HAMEED	M/63	DEGENERATIVE	2-5 years	ONLY LEG PAIN	ABSENT	CONSERVATIVE
21)	LATIKA	F/54	DEGENERATIVE	2-5 years	ONLY LEG PAIN	PRESENT	DECOMPRESSI ON & FUSION
22)	MUSHTAQ	M/45	COMBINED	6 months-1 year	BACK & LEG PAIN	ABSENT	DECOMPRESSI ON & FUSION
23)	RAKESH	M/43	SPONDYLOLYTIC	1-2 years	ONLY BACK PAIN	ABSENT	CONSERVATIVE
24)	SHANTABAI	F/64	DESIGNATIVE	>5 years	ONLY LEG PAIN	ABSENT	CONSERVATIVE
25)	AFREEN	F/47	COMBINED	1-2 years	BACK & LEG PAIN	ABSENT	DECOMPRESSI ON & FUSION
26)	CHHAYA	F/54	DEGENERATIVE	2-5 years	ONLY LEG PAIN	ABSENT	CONSERVATIVE

27)	MANISHA	F/55	DEGENERATIVE	2-5 years	ONLY LEG PAIN	PRESENT	DECOMPRESSION ONLY
28)	KALPANA	F/40	COMBINED	1-2 years	BACK & LEG PAIN	ABSENT	DECOMPRESSION, FUSION & INST.
29)	LALCNAND	M/45	COMBINED	1-2 years	BACK & LEG PAIN	ABSENT	DECOMPRESSION & FUSION
30)	HARPREET	F/45	SPONDYLOLYTIC	1-2 years	ONLY BACK PAIN	ABSENT	CONSERVATIVE
31)	SOHAN	M/50	DEGENERATIVE	6 months-1 year	ONLY LEG PAIN	PRESENT	CONSERVATIVE
32)	YASMEEN	F/43	SPONDYLOLYTIC	1-2 years	BACK & LEG PAIN	ABSENT	DECOMPRESSION, FUSION & INST.
33)	GAYATRI	F/48	COMBINED	1-2 years	BACK & LEG PAIN	ABSENT	DECOMPRESSION & FUSION
34)	ASHWINI	F/49	COMBINED	1-2 years	BACK & LEG PAIN	ABSENT	DECOMPRESSION ONLY
35)	DINESH	M/53	DEGENERATIVE	2-5 years	ONLY LEG PAIN	PRESENT	DECOMPRESSION ONLY
36)	POOJA	F/39	SPONDYLOLYTIC	0-6 months	ONLY BACK PAIN	ABSENT	CONSERVATIVE
37)	HITEN	M/40	COMBINED	6 months-1 year	BACK & LEG PAIN	ABSENT	CONSERVATIVE
38)	PARVATI	F/60	DEGENERATIVE	1-2 years	ONLY LEG PAIN	ABSENT	CONSERVATIVE
39)	RAJAMMA	F/50	DEGENERATIVE	1-2 years	ONLY LEG PAIN	PRESENT	DECOMPRESSION ONLY
40)	KAMALA	F/48	COMBINED	1-2 years	BACK & LEG PAIN	ABSENT	DECOMPRESSION & FUSION