

**MIDTERM CLINICAL EVALUATION OF A NEW
DESIGN SHOULDER HEMIPROSTHESIS IN
RESPECT TO INDIAN SCENARIO**



A DISSERTATION SUBMITTED TO
UNIVERSITY OF SEYCHELLES
AMERICAN INSTITUTE OF MEDICINE
IN PARTIAL FULFILLMENT OF THE REGULATIONS FOR THE
AWARD OF

M.Ch. Orthopaedics

June 2009

Author:

Dr. Amitava Narayan Mukherjee,

M.S. (Orthopedics), M. Sc. (Ortho.&Rehab.), Ph.D.

Head of the Department, Orthopaedics

J. N. Roy Sishu Seva Bhavan and Hospital and Anandalok
Hospital, Kolkata, India

B. Introduction

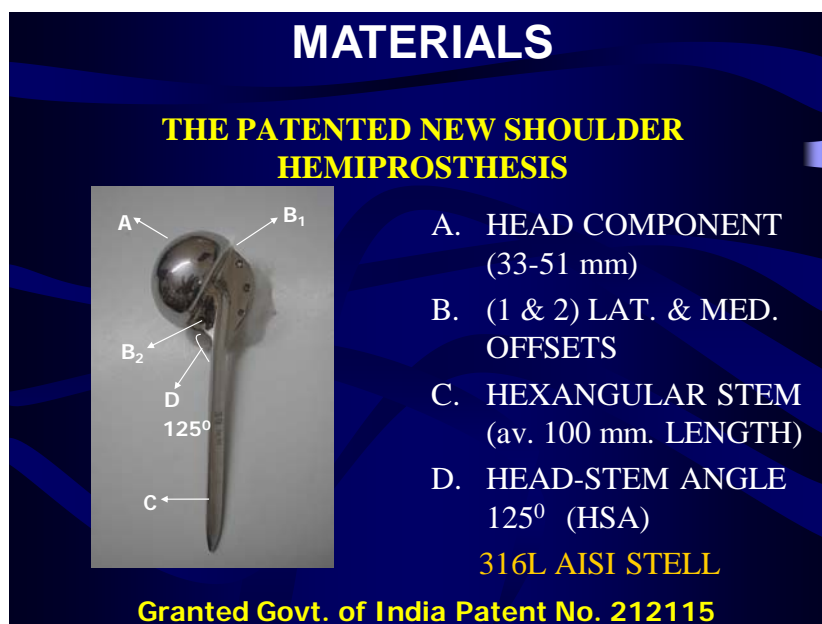The shoulder joint is a polyaxial ball and socket joints requires special attention regarding the management of its structural damage. In the different pathological conditions like fracture-dislocations, neoplasm of humeral head where the structure reconstruction is very difficult, in the presence of normal glenoid hemireplacement of humeral head is the treatment of choice. But the existing design of shoulder hemiprostheses is not suitable for Indian bones which are morphological different from the bones of caucasian people of the Western world. Moreover, anatomical mismatch of the articular congruity may lead to eccentric loading resulting in excessive wear of each surfaces. Therefore, the anatomical parameter of Indian bones were evaluated on the basis of those parameters a newly design shoulder hemiprostheses suitable in Indian Scenario was fabricated.

The objective of midterm clinical evaluation of a new design shoulder hemiprostheses was to evaluate the clinicoradiological outcome of a newly designed shoulder hemiprosthetic replacement for fracture / fracture-dislocations or pathology of humeral head in Indian Scenario.

C. Materials and Methods

MATERIAL I : A NEW DESIGN SHOULDER HEMIPROSTHESIS .

On the basis of parameters of cadaveric study, the new prosthesis was fabricated of 315L AISI (American Iron & Steel Institute) steel with Govt. of India, Patent No.212115⁸. The components of this shoulder hemiprostheses are head, stem, lateral and medial offset, the whole assembly weighs nearly 150 gm which is very much compatible to Indian scenario.



The newly designed shoulder hemiprosthesis

MATERIAL II : THE PATIENTS

In this series 51 patients were selected for study of which 45 had 3 or 4 part fracture / fracture dislocations of the shoulder joint like other series^{1,2,3 & 4}, 3 cases of GCT with pathological fracture of proximal humerus⁵ and 3 head split fractures. Most patients were elderly with mean age 54.3 years. There were 21 male and 30 female and 28 on right side & 23 on the left. In the series, 6 patients were in the age group 25-35 yrs, 5 in the group 35-45 yrs., 11 in the 45-55 group and the remaining 29 were aged > 55 yrs as in Table I (a). Fracture pathology wise 13 cases sustained three part fracture of proximal humerus 17 cases sustained four part fracture, 15 cases were four part fracture with dislocation of proximal humerus. 3 patient sustained head-split fracture with dislocation and 3 patient sustained pathological fracture due to G.C.T. of proximal humerus as shown in Table I (b)

Table I (a):

MATERIALS					
Age distribution of total 51 pts.	TOTAL		NO 51		
	<u>25-35 yrs.</u>		<u>35-45 yrs.</u>	<u>45-55 yrs.</u>	<u>>55 yrs.</u>
	6		5	11	29
Sex	M	21	Side	Right	28
	F	30		Left	23
<u>Duration of study</u>					
August 2001			July 2008		Mean follow up 5.6 yrs.

Table I(b) :

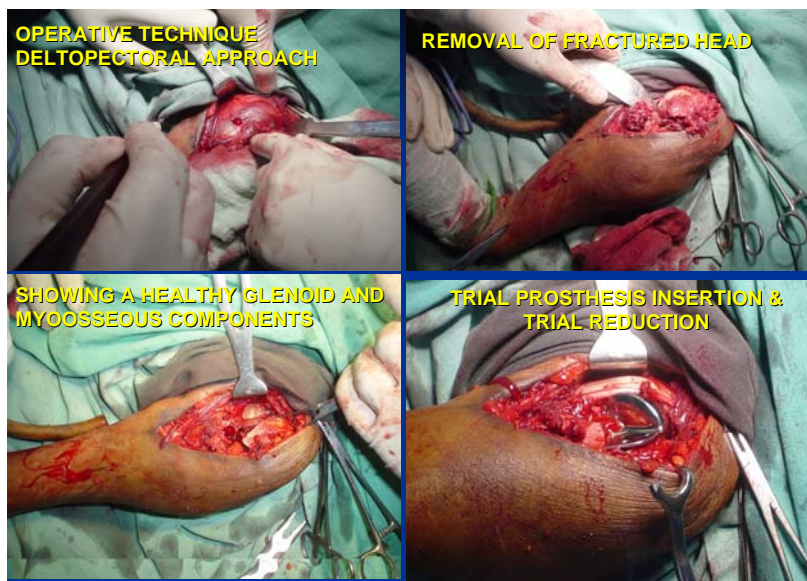
MATERIALS	
Indications for shoulder Hemiarthroplasty (Cemented Stem – 46, Uncemented – 5, Total – 51)	
Indication	No. of cases
3 part fracture of proximal humerus	13
4 part fracture of proximal humerus	17
4 Part Fracture with dislocation of proximal humerus	15
Head split of proximal humerus	3
GCT Prox. Hum of proximal humerus	3

METHODS : The surgical approach and Technique

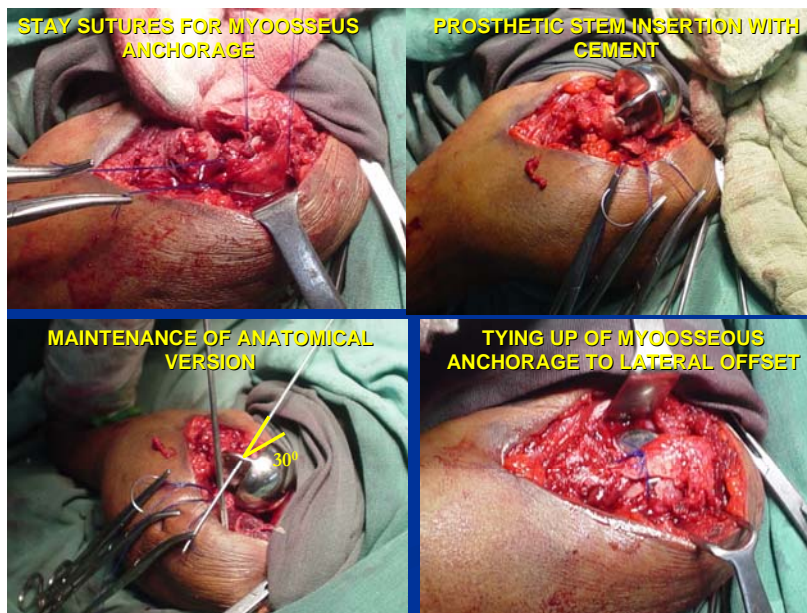
This newly designed shoulder hemiprosthesi s was used for replacement hemiarthroplasty with cement fixation in 46 and uncemented in 5 patients

The patient is kept supine with a bolster kept under the shoulder. Under Regional / GA, deltopectoral approach is made. Proximal humerus is delivered through the

The surgical approach and Technique



The surgical technique



wound by extension, abduction and external rotation. The humeral head if fragmented is removed taking care to preserve the greater & lesser tuberosity with their attachment to rotator cuff. Trial insertion of prosthesis done to denote the up-down and anteroposterior sliding movement in respect to glenoid ⁶. Upto 50% of sliding in any

direction is permissible. Otherwise, if the placement of prosthetic head is too high in respect to glenoid much bone to be cut from proximal humeral shaft for proper sitting. Then either No.20 stainless steel wire or non absorbable sutures (No.1 Ethibond or Prolene) were passed separately from greater, lesser tuberosity and through drill holes of proximal humeral shaft for their anchorage. Preparation of medullary canal of proximal humerus done by specially made reamers. Proper size of the prosthesis is selected on the basis of diameter of removed humeral head and inserted with the help of bone cement maintaining the normal 30° retroversion with special instrument. Then bridging bone grafts, taken from humeral head are placed between tuberosities and proximal humeral shaft. Reduction of prosthesis done with completion of myosseous anchorage using the wires / non absorbable sutures as per figure, already passed against the offsets of the prosthesis. Peroperative range of motions tested and wound closed in layers with placement of drain.

Post operative care : Postoperatively, arm to chest strapping applied. Dressing changed on 5th postoperative day. Stiches removed on 10th to 12th postoperative day. Active range of motion exercises especially flexion and extension started after second week, followed by rotations of the shoulder. Abduction of the shoulder is allowed from six to eight weeks after operation.

D. Outcomes

The outcome of this series was evaluated on the following recorded tabular criterias. These criterions were taken in consideration to score this series in UCLA, Constant & Murley and Neer shoulder scoring system. Here Table II(a) shows pain around the shoulder, Table II(b) shows stability of shoulder, Table II(c) for component loosening, stem failure etc. Table III(a) shows ability to perform daily activities, Table III(b) shows Functional results and Table III(c) shows the level of ability to work. Table IV(a) shows forward flexion and Table IV(b) shows active abduction. Table V(a) shows combined active internal, Table V(b) combined active external rotations and Table V(c) patient's satisfaction.

E. Analysis

The study period of this series was from August, 2001 to July, 2008 with a mean follow up period of 5.6 years. There were total 51 patients treated by shoulder hemi

Table II(a,b & c)

RESULTS			
Clinical Evaluation			
Pain	No. of patients	Stability of Shoulder	No. of pts.
Present always & unbearable, Strong Medicine	0	Stable	49
Present always but bearable.Occasional medicine	0	Unstable	2
No Pain at rest /only on light activities	1	Total cases	51
Pain on heavy activities only	3	Radiological Evaluation	
Occasional & Slight	7	Conditions	No. of cases
No pain	40	Proper fit stem	49
TOTAL	51	Stem Loosening	1
		Extrusion of stem	1

Table III(a,b & c)

RESULTS					
Function	No. of patients	Functions		Ability to work at the level :	No. of patients
Unable to use limb	0	Function	No. of patients	Of the waist	1
Only light activities possible	1	Ability to work	32	Of the Xiphoid	9
Light housework or ADLs	3	Recreational activities	15	Of the neck	17
Driving, Shopping, Dress & Undress, Hair dressing	2	Ability to sleep	4	Of the head	14
Work above shoulder level- Slight restriction only	13	Total	51	Above the head	10
Normal activities	32			Total	51
TOTAL	51				

replacement and were assessed in the aforementioned follow up period. The Range of Motion was quite satisfactory in the patients following shoulder hemiarthroplasty. The

average abduction was about 90 degree with 31 cases. The average combined internal rotation – hand to T 12 was in 37 cases. The Average Active Forward Flexion is 100 degree with Grade 4 strength in 39 cases. The Average Combine Active External Rotation – hand behind the head and elbow back was in 38 cases.

In this series, 40 patients experienced no pain while 11 cases had mild pain. All the operated patients had a stable shoulder. 49 cases had proper fit stem while 2 patients had stem complications.

Table IV(a & b)

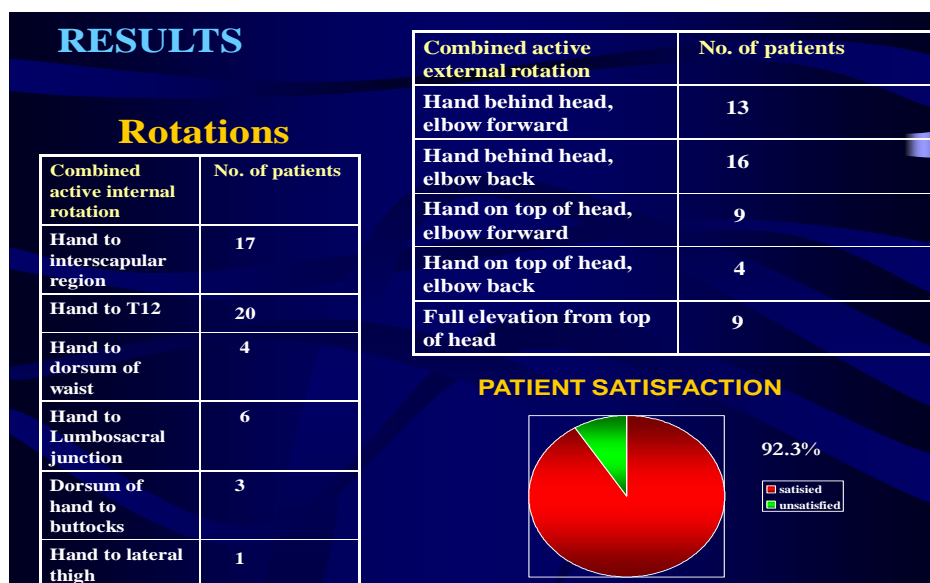
RESULTS			
FORWARD FLEXION			
Active Forward Flexion (Degree)	No. of Patients	Strength of Forward Flexion (Grade)	No. of Patients
>150	11	5	29
120 - 150	13	4	12
90 - 120	16	3	6
45 - 90	8	2	3
30 - 45	2	1	1
< 30	1	0	-

Active Abduction	
Range	No.of patients
151° - 180°	0
121° - 150°	8
91° - 120°	10
61° - 90°	29
31° - 60°	3
0° - 30°	1

In complications, 1 patient had extrusion of prosthesis stem, while 1 had a radiolucency around uncemented stem, but they were quite happy with their clinical range of movement, superior migration of Greater Tuberosity in 1, subluxation / Dislocation in 1 and Superficial Infection in 2 cases.

The final evaluation of this series was done by different shoulder scoring systems and respective results were observed - in UCLA shoulder scoring system it is found to be 29.69, which is good, as per Constant & Murley system the score is 53.86 and in Neer shoulder score it is 81.38 which is satisfactory.

Table V (a, b & c) :



F. Discussion

On the basis of Indian cadaveric study ^{7,12} the parameters found were - average humeral head size - 41mm (33mm - 51mm), average head shaft angle-125⁰ (115⁰-135⁰), average diameter of proximal humeral medullary canal - 9 mm (8-12mm), average anatomical version - 30⁰ retroversion (25⁰ - 40⁰) a new designed shoulder hemiprosthesis was fabricated which is anatomically and biomechanically suitable for Indian patients. Anatomically compatible design helps anatomical reconstruction of humeral head to restore the physiological motion and to limit eccentric loading of the glenoid ^{7,10,11,13&14}.

Pain relief is the most important objective following shoulder hemiarthroplasty and most of our patients 92.3% regained satisfactory painless stable shoulder motion specially 90⁰ abduction which is similar to other series ^{9,15&16}. On overall basis 47 cases (92.3%) became satisfied with painless stable shoulder motion with satisfactory functional outcome of their shoulder following hemiarthroplasty. 4 cases (7.7%) became unsatisfied; 1 due to recurrence of pain of rheumatoid arthritis, 1 due to subluxation / dislocation of the shoulder joint and 2 due to improper repair of

myosseous anchorage in the cases of G.C.T. where the whole proximal humerus was excised.

G. Conclusions and Recommendations

Based on the analysis and the mid term clinical evaluation of this series of newly designed shoulder hemiarthroplasty performed on 51 patients of different pathologies the following conclusions and recommendations may be drawn.

1. The unique feature of the newly designed patented shoulder hemiprosthesis are its spherical head, a stem, a medial offset and lateral offset components. The head stem components are held at an angle of 125° . The cross section of the stem component is substantially triangular. While the medial offset component has a flat base. For obvious reason of flexibility and medialisation, the angle between lateral offset component and the stem component is maintained at 15° .
2. The cases were evaluated from 2001 August to June 2008 with a mean follow up period 5.6 years. Clinical evaluation was done on the basis of pain, stability, range of motions, functional outcome / ADLS of the replaced shoulder and patient satisfaction. 31 cases regained painless average 90° abduction with satisfactory functional activity. Extrusion of prosthetic stem occurred in 1 and radiolucency around uncemented stem 1 with satisfactory function. Unsatisfactory functional results were due to reactivation of rheumatoid arthritis, subluxation / Dislocation in shoulder hemiprosthesis and improper repair of Myosseous Anchorage in GCT of humeral head. To sum up the midterm clinical evaluation of this series results were evaluated under UCLA shoulder scoring system and found to be 29.69, which is good, as per Constant&Murley system the score is 53.86 and in Neer shoulder score it is 81.38 which is satisfactory
3. As a recommendations this newly designed shoulder hemiprosthesis may be considered as a viable option for replacement in fracture / fracture – dislocation / pathologies of proximal humerus for the Indian patients.

REFERENCES

1. Bosch U, Fremerey RW, Skutek M, Lobenhoffer P, Tscherne H. Unfallchirurgische Klinik, Medizinische Hochschule Hannover ; Unfallchirurg. 1996 Sep+Ads-99 (9) :656-64. Related Articles, Hemi-arthroplasty—primary or secondary measure for 3- and 4- fragment : Fractures of the proximal humerus in the elderly Article in Polish.
2. Schittko A, Braun W, Ruter A., Klinik Fur Unfall and Wiederherstellungschirurgie. Andreas.schittko ; Zentralbl Chir. 2003 Jan+Ads-128 (1) : 12-6-Related Articles : Experiences with the OrTra-prosthesis in primary prosthetic replacement of fractures of the humeral head-indication, technique and results.
3. Heers G, Torchia ME.; Shoulder hemi-arthroplasty in proximal humeral fractures- Article in Germany : Orthopade . 2001 Jun + Ads-30(6) : 386-94.
4. Clin Orthop ; Dines DM, Warren RF: Department Orthopedic Surgery, Cornell University Medical College; Modular shoulder hemiarthroplasty for acute fractures. Surgical considerations : 1994 Oct+Ads-(307):18-26.
5. Pe'an JE 1978. Campbell's Operative Orthopedics (Edn. VII, 767).
6. Chirug. Indication and technique for shoulder endoprotheses in fractures. 2001 Nov+Ads-72(11) : 1246-52.
7. WBOA Journal, Vol. 19, No. 1, 2004; page – 7; Evolution of a design of a new shoulder prosthesis on the basis of cadaveric study; Dr. A. N. Mukherjee, A. K. Pal, P. Bhattacharya & S. Dutta.
8. A SHOULDER HEMIPROSTHESIS FOR INDIAN SCENARIO inventor Amitava Narayan Mukherjee, Patent Application: 113/KOL/2005, Filing date: 2005-02-18, Publication date: 2005-07-29, Govt. of India, Granted Patent No.212115
9. WBOA Journal Vol. 20, No.1, Sep. 2005; page-55; A short term clinical experience of a newly designed shoulder hemiprosthesis, suitable in Indian scenario. Dr. A. N. Mukherjee, Dr. A. K. Pal, Dr. D. S. Roy, Dr. D. Banerjee, Dr. S. Nandy, Dr. M. Saha.
10. WBOA Journal Vol. 22, No.1, Feb. 2007; page-39; The in-vitro biomechanical study of the newly designed shoulder hemiprosthesis. Dr. A. N. Mukherjee, A. K. Pal, M. Saha, S. Nandy & D. Baksi
11. "The Bio mechanical study of the newly designed shoulder hemiprosthesis for satisfactory functional outcome suitable for Indian scenario" by A.N. Mukherjee, A.K. Pal, S. Nandy, D.D. Baksi, D. Banerjee has been published in "Indian Journal of Biomechanics" (IJB).Volume-1, No.1, June 2007, ISSN 0974-0783, Page-95-100.
12. "Design of A New Shoulder Prosthesis, and its Biomechanical and Clinical Analysis in respect to Indian Scenario, Ph.D thesis; Jadavpur University, Kolkata –700032; Year- 2006.
13. Pearl ML, Yolk AG : Retroversion of the proximal humerus in relationship to prosthetic replacement arthroplasty. J Shoulder Elbow Surg 1995;4:286-289.
14. Buchler P, Farron A : Benefits of an anatomical reconstruction of the humeral head during shoulder arthroplasty. Clin Biomech (Bristol, Avon). 2004 Jan + Ads-19(1) : 16-23.
15. Neer CS II : Articular replacement for the humeral head. J Bone Joint Surg 1964;46:1607-1610.
16. Norris TR, Ionnotti JP. Functional outcome after shoulder arthroplasty for primary osteoarthritis : a multicenter study. J Shoulder Elbow Surg. 2002 Mar-Apr + Ads-11(2) : 130-5.